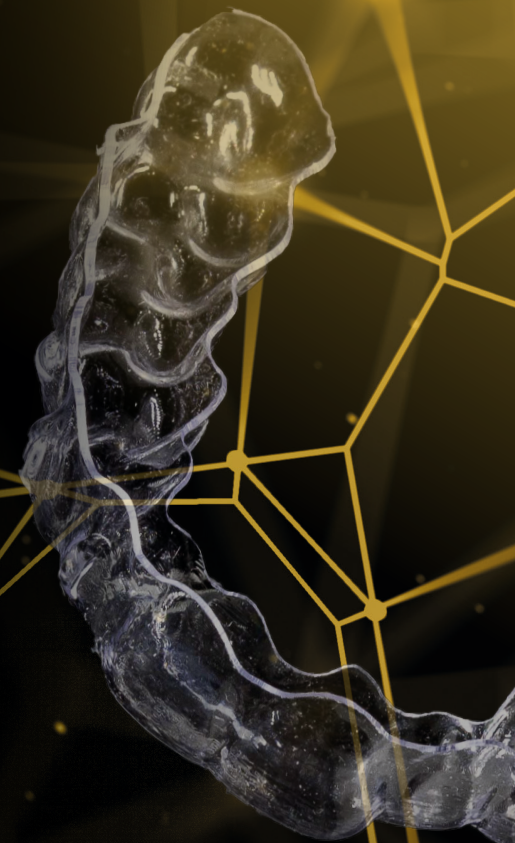
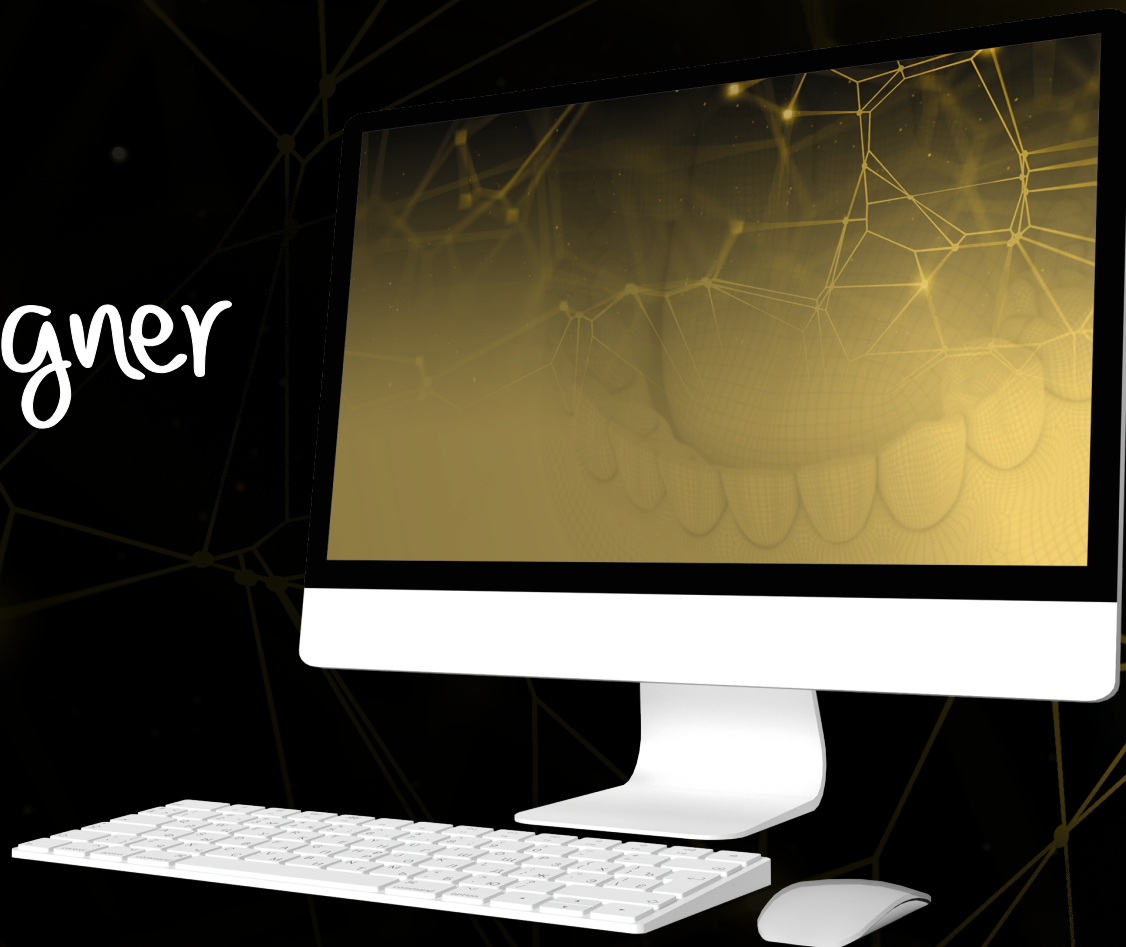

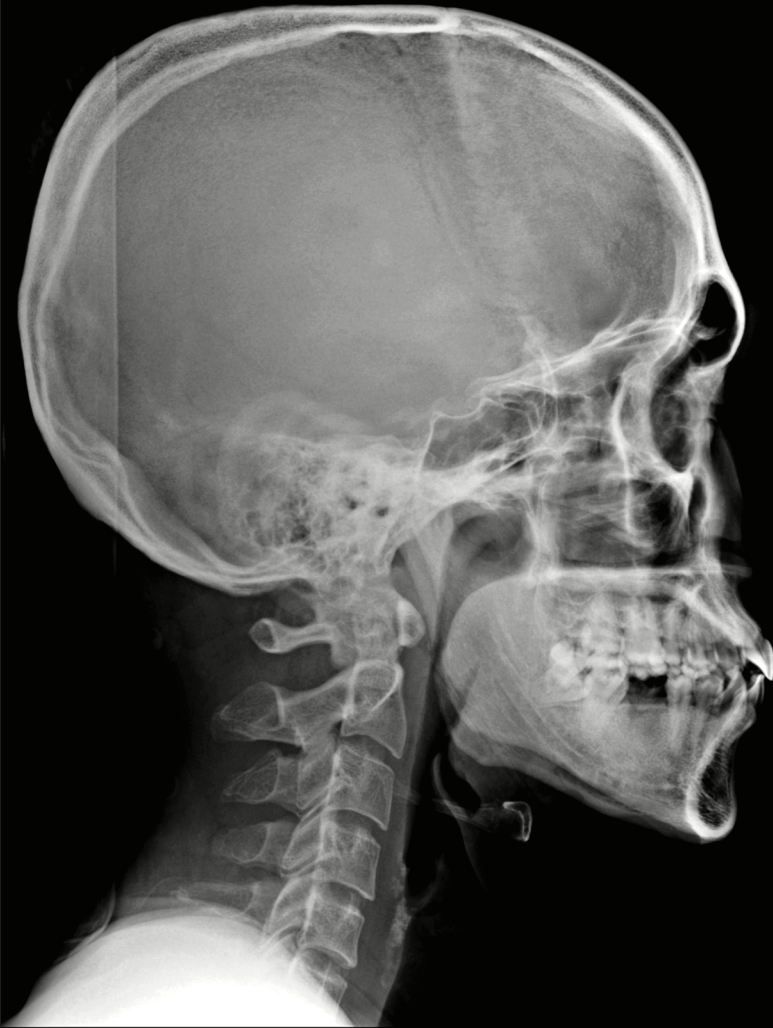Case report

RealAligner

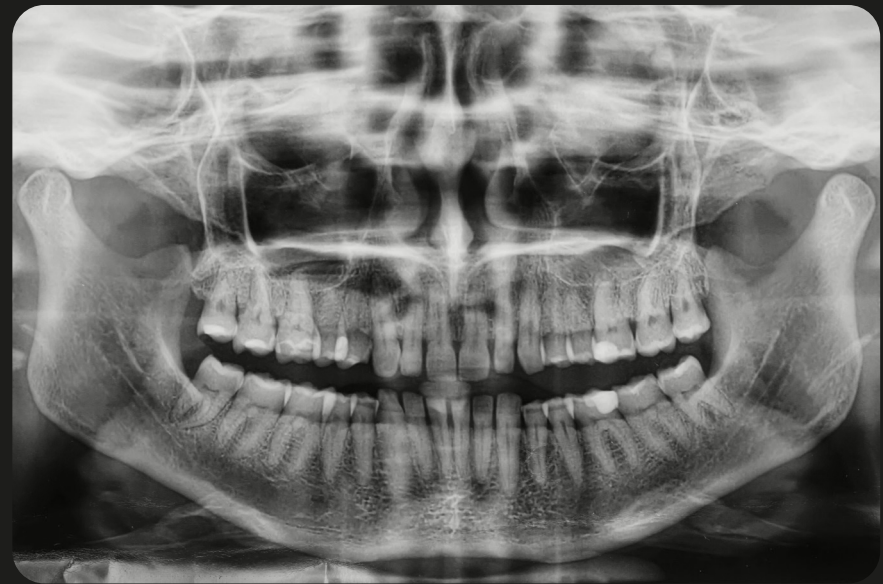

X-rays

Lateral view of skull



Panoramic view



Extra-oral photographs

Frontal view



Frontal view with smile



Profile view

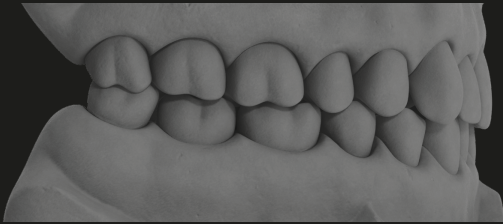


Three-quarter view

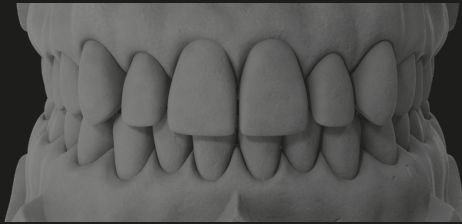


Intra-oral photographs

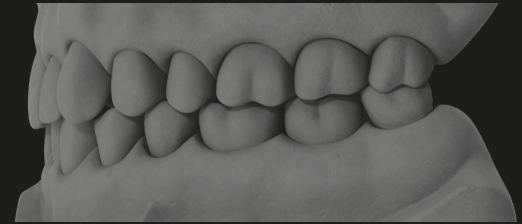
Right



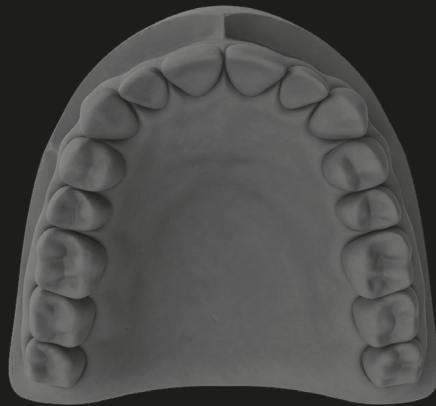
Occlusal view



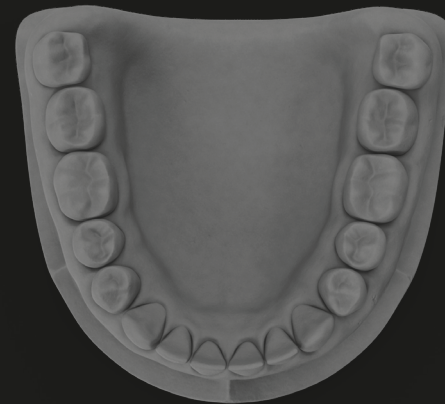
Left



Maxillary arch



Mandibular arch





*Real*Aligner